

DOI: <http://dx.doi.org/10.18203/2320-1770.ijrcog20203346>

Case Report

## Ruptured cornual ectopic pregnancy: a case report

Arti Sharma\*, Dipika Singh, Sarika Verma

Department of Obstetrics and Gynecology, ESI Hospital, Okhla, New Delhi, India

**Received:** 02 June 2020

**Accepted:** 06 July 2020

**\*Correspondence:**

Dr. Arti Sharma,

E-mail: [mycontact07@gmail.com](mailto:mycontact07@gmail.com)

**Copyright:** © the author(s), publisher and licensee Medip Academy. This is an open-access article distributed under the terms of the Creative Commons Attribution Non-Commercial License, which permits unrestricted non-commercial use, distribution, and reproduction in any medium, provided the original work is properly cited.

### ABSTRACT

A cornual gestation is one of the most hazardous and life-threatening type of ectopic pregnancy with a mortality rate of 2-5 times higher than other ectopic pregnancies. Because of the myometrium stretch ability, they usually present late around 7-12 weeks of gestation. Thus, the diagnosis and treatment of such cases become challenging. In the case of ruptured cornual ectopic pregnancy, the patient usually presents with hemodynamic instability. Presenting a case report of a 28-year-old female who presented to the labour room of ESI hospital, Okhla, New Delhi at 12 weeks of pregnancy in a state of shock. A provisional diagnosis of ruptured cornual ectopic was made based on clinical examination and ultrasound report. Resuscitation followed by emergency laparotomy done as a life-saving procedure for the patient. Ruptured cornual ectopic needs urgent intervention and multidisciplinary approach. However, with the advancement and expertise in the field of radiology and early diagnosis can be made which can contribute towards more conservative management of such cases.

**Keywords:** Cornual pregnancy, Ectopic pregnancy, Ruptured cornual pregnancy

### INTRODUCTION

Ectopic pregnancy is the result of implantation and maturation of conceptus outside the endometrial cavity. Without timely diagnosis and management, ectopic pregnancy can become a life-threatening situation.<sup>1</sup> The definition of Cornual ectopic pregnancy is still debated. Most of the authors accept 'interstitial' and 'cornual' as synonyms. However, some use the 'cornual' term in pregnancies developed in the bicornuate or septate uterus.<sup>2,3</sup> By definition, a cornual pregnancy refers to the implantation and development of a gestational sac in one of the upper and lateral portions of the uterus. Conversely, an interstitial pregnancy is a gestational sac that implants within the proximal, intramural portion of the fallopian tube that is enveloped by the myometrium.<sup>4,5</sup>

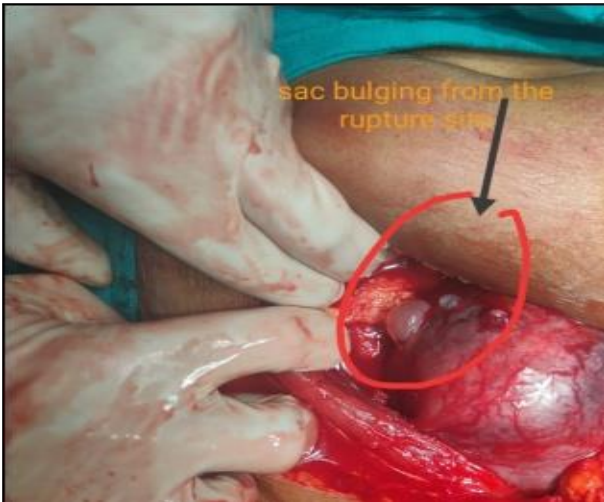Cornual pregnancies often rupture later than other tubal pregnancies because myometrium is more distensible. For this reason, the mortality risk is 2-5 times more than other ectopic pregnancies.<sup>6,7</sup> It is difficult to diagnose an

interstitial ectopic pregnancy before the rupture; however, early diagnosis and treatment of this condition are essential for reducing morbidity and mortality risk. In the general population, the incidence of ectopic pregnancy is about 2%.<sup>8</sup> Interstitial pregnancies account for 2-4 % of ectopic pregnancies and that 20 % of cases that advance beyond 12 weeks of gestation end in rupture.<sup>2</sup>

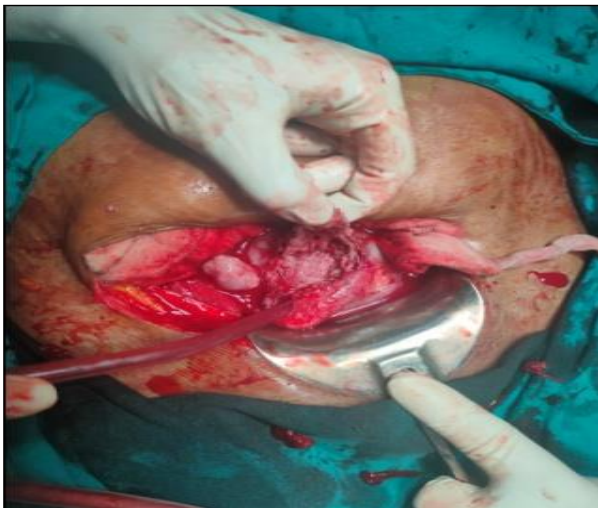
Here authors present a case of a 28-year-old, unbooked patient with ruptured cornual ectopic pregnancy.

### CASE REPORT

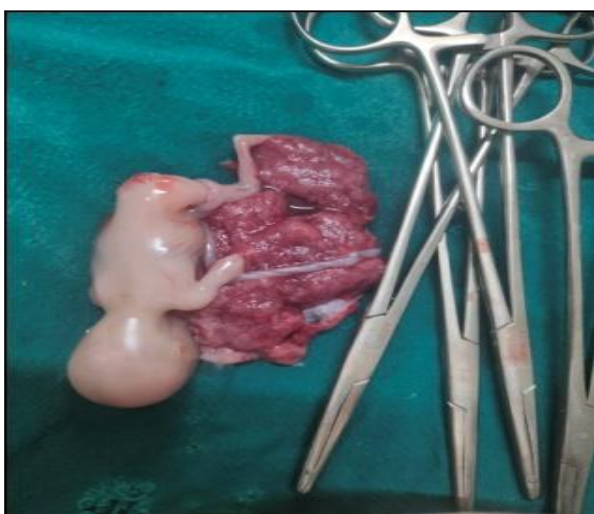A 28-year-old, G2P1L1 presented to the labour room at 12 weeks pregnancy (by date) with the complaint of abdominal pain associated with vomiting for 6 hours. She had severe abdominal pain for 6 hours with multiple episodes of vomiting. She was conscious and disoriented at the time of examination. She was afebrile with a pulse rate of 126/min and BP 70/50 mmHg with SPO<sub>2</sub> 80%.



**Figure 1: Ruptured right cornua of the uterus with gestational sac bulging through it.**



**Figure 2: Cornual bed after removal of gestational sac.**



**Figure 3: Fetus with placenta.**

She had signs of severe dehydration with severe pallor. On per abdominal examination, there was severe tenderness all over the abdomen. Pelvic examination revealed retroverted uterus with bilateral fornical tenderness along with cervical motion tenderness. The patient was carrying an ultrasound report conducted on the previous day in a private diagnostic lab suggestive of bicornuate uterus with single live intrauterine pregnancy corresponding to 10 weeks 2 days in right cornua of the uterus.

Based on her clinical findings and ultrasound report, a diagnosis of ruptured cornual ectopic pregnancy was made and the patient was taken up for laparotomy after basis resuscitation. Her preoperative laboratory test revealed Hb 5.4 gm%, blood group B positive and BT/CT within normal limits. The past obstetric history she had a full-term normal vaginal delivery 14 years back, delivered a male child who is alive and healthy. The entire antenatal and postnatal period was uneventful.

Due consent was taken by the attendant before proceeding with the laparotomy and 4 PRBC and 2 Platelets were arranged.

Emergency laparotomy was performed under general anesthesia using universal precautions. Around 2000 ml of blood along with 300 gms of the blood clot was removed on opening the abdominal cavity. Ruptured right cornual ectopic pregnancy with gestational sac bulging out was seen (Figure 1). Bilateral adnexa appeared normal. However, the uterus appeared normal without any finding suggestive of a bicornuate uterus.

A nick was given over the bulging sac and the entire product of conceptus was removed (Figure 2). The cornual bed was sutured using Vicryl no 2 (Figure 3). Complete hemostasis was obtained, Drain was put and abdomen was closed in layers after mop and instrument count. Postoperatively she was kept in ICU for one day and transfused 4-unit PRBC along with 2-unit platelets. She was later shifted to HDU, check dressing and removal of drain and catheter was done on day 3 and she was discharged on day 7 in good health.

## DISCUSSION

Early recognition of cornual and interstitial pregnancy is crucial as it is one of the life-threatening emergencies, especially in underdeveloped and developing countries. Clinical presentation of cornual pregnancy depends on whether it is ruptured or unruptured cornual ectopic.

In unruptured cornual pregnancy, the diagnosis becomes difficult, the patient can complain of on and off abdominal pain. However, in experienced hand, TVS can establish a diagnosis of cornual ectopic in nearly 71% of cases.<sup>9</sup>

In the case of ruptured cornual pregnancy, the patient usually presents with severe abdominal pain, vomiting and hemodynamic instability and in such cases, laparotomy becomes a life-saving procedure.

Traditionally, the treatment of interstitial and cornual pregnancy has been laparotomy, cornual resection or hysterectomy.<sup>10</sup> However, in hemodynamically stable patients, conservative measures may be attempted including medical management and laparoscopy such as laparoscopic cornual resection, laparoscopic cornuostomy or hysteroscopic removal of interstitial ectopic tissue, unilateral uterine artery ligation has been tried.<sup>11</sup> Medical methods such as systemic methotrexate or USG guided local injection of methotrexate is a safe and highly effective treatment for cornual pregnancy so that surgery can be avoided.<sup>12</sup>

*Funding: No funding sources*

*Conflict of interest: None declared*

*Ethical approval: Not required*

## REFERENCES

1. Farquhar CM. Ectopic pregnancy. *Lancet.* 2005;366:583-59.
2. Lau S, Tulandi T. Conservative medical and surgical management of interstitial ectopic pregnancy. *Fertil Steril.* 1999;72(2):207-15.
3. Dorfman SF, Grimes DA, Cates W, Binkin NJ, Kafrisen ME, O'Reilly KR. Ectopic pregnancy mortality, United States, 1979 to 1980: clinical aspects. *Obstet Gynecol.* 1984;64(3):386-90.
4. Malinowski A, Bates SK. Semantics and pitfalls in the diagnosis of cornual/interstitial pregnancy. *Fertil Steril.* 2006;86(6):1764.e11-4.
5. Kun W, Tung W. On the lookout for rarity-interstitial/cornual pregnancy. *Emerg Med J.* 2001;8:147-50.
6. Chang Y, Lee JN, Yang CH, Hsu SC, Tsai EM. An unexpected quadruplet heterotopic pregnancy after bilateral salpingectomy and replacement of three embryos. *Fertil Steril.* 2003;80(1):218-20.
7. Timor-Tritsch IE, Monteagudo A, Matera C, Veit CR. Sonographic evolution of cornual pregnancies treated without surgery. *Obstet Gynecol.* 1992;79(6):1044-9.
8. Abusheika N, Salha O. Extra-uterine pregnancy following assisted conception treatment. *Human Reprod Update.* 2000;6(1):80-92.
9. Abraham D, Silkowski C. Emergency medicine sonography 1<sup>st</sup> ed; 2010:264-27.
10. Katz DL, Barrett JP, Sanfilippo JS, Badway DM. Combined hysteroscopy and laparoscopy in the treatment of interstitial pregnancy. *Am J Obstet Gynecol.* 2003;188:1113-4.
11. Bernstein HB, Thrall MM, Clark WB. Expectant management of intramural ectopic pregnancy. *Obstet Gynecol.* 2001;97:826-7.
12. Hafner T, Aslam N, Ross JA, Zosmer N, Jurkovic D. The effectiveness of non-surgical management of early interstitial pregnancy: a report of ten cases and review of the literature. *Ultrasound Obstet Gynaecol.* 1999;13(2):131-6.

**Cite this article as:** Sharma A, Singh D, Verma S. Ruptured cornual ectopic pregnancy: a case report. *Int J Reprod Contracept Obstet Gynecol* 2020;9:3483-5.