

DOI: <http://dx.doi.org/10.18203/2320-1770.ijrcog20195588>

Case Report

Sirenomelia with Potter syndrome: a case report and review of literature

Amrita Singh^{1*}, Anupma Kumari²

¹Department of Obstetrics and Gynecology, Lady Hardinge Medical College and Hospitals, New Delhi, India

²Department of Obstetrics and Gynecology, All India Institute of Medical Sciences, Rishikesh, Uttarakhand, India

Received: 21 November 2019

Accepted: 02 December 2019

***Correspondence:**

Dr. Amrita Singh,

E-mail: drsinghamrita@gmail.com

Copyright: © the author(s), publisher and licensee Medip Academy. This is an open-access article distributed under the terms of the Creative Commons Attribution Non-Commercial License, which permits unrestricted non-commercial use, distribution, and reproduction in any medium, provided the original work is properly cited.

ABSTRACT

Sirenomelia or mermaid syndrome is a rare congenital anomaly characterized by variable degree of fusion of lower extremities. Awareness to this rare condition is important for prenatal diagnosis and prognosticating the fetus. The exact etiopathogenesis is still an area of research. Two pathogenic hypotheses are the vascular steal hypothesis and the defective blastogenesis hypothesis with exceptions reported in literature.

Keywords: Anhydramnios, Congenital anomaly, Limb deformity, Mermaid syndrome, Potter syndrome, Sirenomelia

INTRODUCTION

Sirenomelia or mermaid syndrome is a rare congenital anomaly characterized by variable degree of fusion of lower extremities. It derived its name because of single axial positioned lower limb which resembles the mythical creature “siren” or “mermaid”.

The birth prevalence of sirenomelia is estimated by Orioli M et al, to be 0.98 per 100,000 births.¹ This typical external phenotype is usually associated with variable combination of several visceral abnormalities most common are genitourinary and gastrointestinal. Single umbilical artery is a common association.

Variable degree of renal and urethral dysplasia is consistently present with genital malformation.

Awareness to this rare condition along with its clinical presentation and associated anomaly is important for prenatal diagnosis which helps in prognosticating the fetus and managing pregnancy accordingly.

CASE REPORT

A 20 years old primigravida female was referred from primary health care facility in view of ultrasound finding suggestive of severe oligohydramnios at 28^{4/7} weeks of gestational age. History was reviewed and there was no history of any medical disorder, substance abuse, medication, chemical or radiation exposure in pregnancy. This pregnancy was a spontaneous conception with a married life of 1^{1/2} years.

She had no complaints and was perceiving good fetal movement. On clinical examination the fundal height was found to correspond 26 weeks of gestational age and liquor was clinically reduced. A detailed anatomical scan was done which showed single live intrauterine fetus with breech presentation with anhydramnios, single umbilical artery, left sided dysplastic kidney and a small urinary bladder, view of right kidney was obscured by fetal shadowing. Although all the anatomical details could not be appreciated precisely owing to anhydramnios. Subsequent ultrasonography showed persistent extended breech with anhydramnios and bilateral dysplastic

kidneys with small urinary bladder. Despite of reduced visibility of complete anatomical details of lower limb owing to anhydramnios, persistent extended breech and static position of lower limb in subsequent ultrasound scan pointed towards this rare congenital entity. Pulmonary hypoplasia was also well anticipated in view of bilateral dysplastic kidneys and anhydramnios. Patient had spontaneous onset of labour at 31^{1/7} weeks of gestational age and delivered a live baby having sirenomelia with Potter sequence with poor APGAR score. Baby died within the first hour of life probably because of pulmonary hypoplasia.

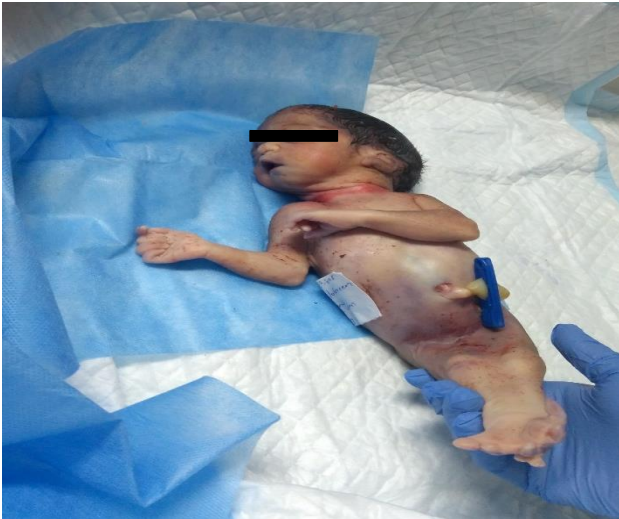

Figure 1: Sirenomelia with potter syndrome (potter's facies with fused lower limb).

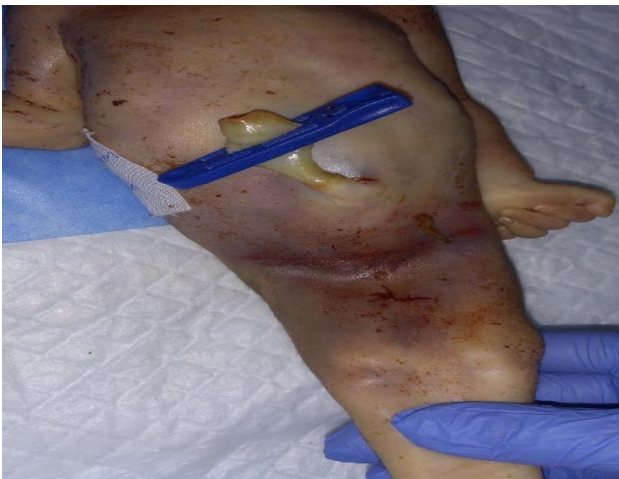

Figure 2: Absent external genitalia in sirenomelia (External genitalia visibly absent presented as a dimple).

External morphological examination showed malformation of lower limb as complete fusion of limbs ending up with fused flip like feet with knob like structure representing phalanges which were seven in number giving a mermaid like appearance. The external genitalia were visibly absent and was represented by

dimple only. There was no urethral and anal opening (Figure 1, 2, 3).

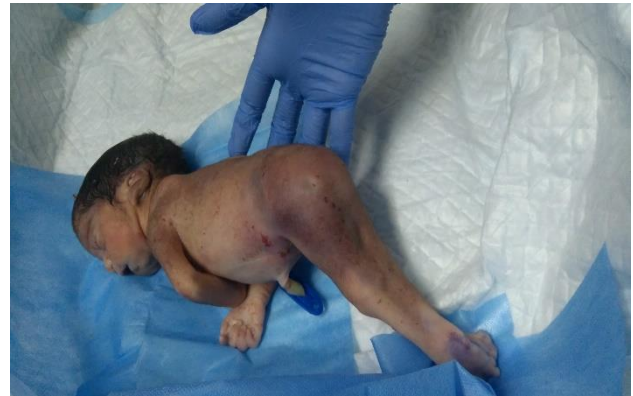

Figure 3: Absent anal opening in sirenomelia.

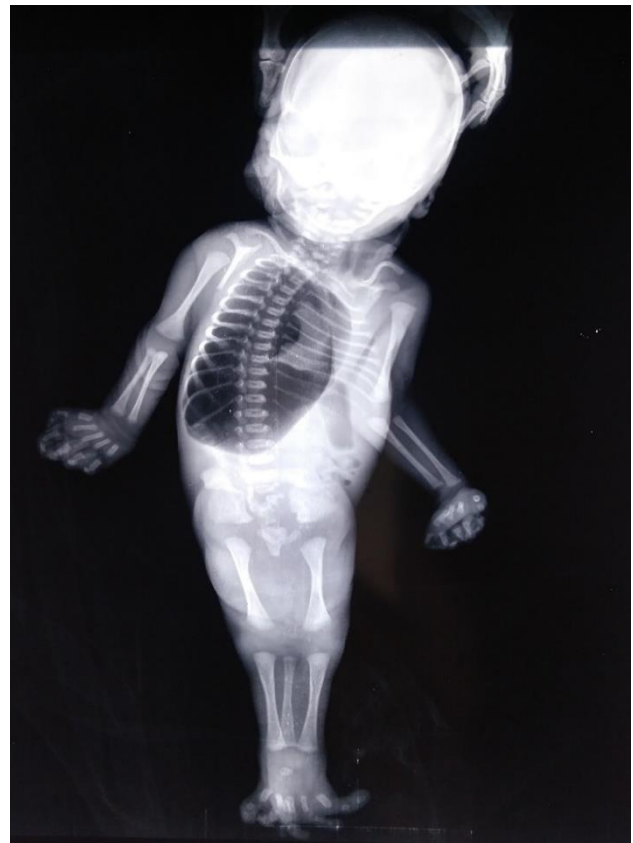


Figure 4: Infantogram showing skeletal deformities (Thoraco-lumbar scoliosis and two tibia with a single fused fibula along with fused flip like feet).

Presence of single umbilical artery in cord was noted. Deformity in vertebral column was noted in the form of thoracolumbar scoliosis. Potter facies was seen as flattened nose, redundant skin epicanthal folds. The ears appeared to be slightly low and pressed against the head making them appear large.

Infantogram showed two femur, two tibia with a single fused fibula along with fused flip like feet with in total

seven phalanges. Thoraco-lumbar scoliosis was present with rib cage abnormality. Due to religious constraints autopsy could not be done abnormalities (Figure 4).

DISCUSSION

Earlier sirenomelia was considered as a part of caudal regression syndrome, now it is classified as a separate entity with its common association. Sirenomelia exhibit wide range of phenotypic variability and shares overlapping characteristics with other conditions like caudal regression syndrome, VACTERL association (VACTERL stands for vertebral defects, anal atresia, cardiac defects, tracheoesophageal fistula, renal anomalies, and limb abnormalities).

Orioli M et al, in their study, 249 cases with sirenomelia were identified among 25,290,172 births. The prevalence found was 0.98 per 100,000 with higher prevalence in the Mexican population. A statistically significant increased prevalence with maternal age less than 20 years was noted. No familial recurrence was found. The proportion of twinning was 9% which was higher than the 1% expected. 47% of Babies born were born with ambiguous genitalia. Almost one half of the cases with sirenomelia were found to have genital, large bowel and urinary defects. 10-15% of the cases had lower spinal column defects, upper limb, single or anomalous umbilical artery, cardiac, and central nervous system defects. There was a greater than expected association of sirenomelia with other very rare defects such as bladder exstrophy, cyclopia/holoprosencephaly, and acardia-acephalus.¹

Widely accepted classification of sirenomelia spectrum was given by Stocker and Heifetz, however other classifications do exist.² Few reports of sirenomelic fetuses are also present which does not fit into this classification. Stocker and Heifetz classified sirenomelia into VII types depending upon presence of skeletal elements of lower limb (Stocker and Heifetz, 1987) (Table 1).

Table 1: Stocker and Heifetz classification of sirenomelia.

Classification	
Type I	All thigh and leg bones are present
Type II	Single fibula
Type III	Absent fibula
Type IV	Partially fused femurs, fused fibulae
Type V	Partially fused femurs
Type VI	Single femur, single tibia
Type VII	Single femur, absent tibia

The exact etiopathogenesis of sirenomelia is still not established. The two main pathogenic hypotheses are the vascular steal hypothesis and the defective blastogenesis hypothesis.

The vascular steal hypothesis was based on presence of large single aberrant umbilical artery and vascular malformation resulting in lack or inadequate blood supply leading to hampered growth of lower part of the body.²⁻⁴ During the course of embryonic development there appears paired vitelline arteries from ventral surface of aorta which later form major branches celiac, superior mesenteric and inferior mesenteric artery normally. In sirenomelia inferior mesenteric artery may be less developed or absent and a persistent vitelline artery may be there which continues as single large umbilical artery however the part of distal aorta may be hypoplastic or end abruptly. All these leads to underdeveloped and undeveloped structures caudally. Heifetz observed a single umbilical artery in all of the 25 included sirenomelic fetuses. However, sirenomelia is also associated with malformation of upper part of the body often less commonly which remains unexplained by this vascular steal theory.^{5,6} Moreover single umbilical artery may be is a consequence of sirenomelia rather than its cause as many reports exist showing two umbilical arteries in fetus with sirenomelia may be at abnormal origin.⁷⁻¹⁰ The association of aberrant umbilical artery is also seen in caudal regression syndrome.¹¹

Another hypothesis is of defective blastogenesis hypothesis explaining the phenotypical appearance of sirenomelia and the overlapping caudal regression syndrome. This hypothesis postulates that sirenomelia is a primary defect of blastogenesis occurring at final stages of gastrulation at the tail bud stage approximately at third week of gestational age and morphology depends upon intensity and duration of underlying event.¹⁰⁻¹²

Another finding in our case was of potter syndrome in the newborn sirenomelic baby. The characteristic facial features in potter facies includes a depressed bridge of the nose, eyes having hypertelorism with prominent epicanthal folds, low-set ears that lack cartilage (Potter ears), a crease beneath the lower lips and a recessed chin. This is usually a part of potter syndrome which is caused mostly due to oligohydramnios. Decreased or absent amniotic fluid does not provide protection of fetus from the walls of the uterus leading to such facial features.¹³

Causes of oligohydramnios include bilateral renal agenesis, dysplastic kidney, polycystic kidney diseases, and prune belly syndrome, urinary tract obstructions, preterm premature rupture of the membranes. In our case it was bilateral dysplastic kidney. Severe oligohydramnios antenatally, poor APGAR score at birth and inability to survive even for early hours of birth points towards pulmonary hypoplasia and all together a potter syndrome in this case.

CONCLUSION

Sirenomelia or mermaid syndrome is a rare congenital anomaly associated with variable combination of genitourinary, gastrointestinal and other abnormalities.

Common presentation is with oligohydramnios and its consequences. Despite several hypothesis the exact etiology is still not known.

Funding: No funding sources

Conflict of interest: None declared

Ethical approval: No required

REFERENCES

1. Orioli IM, Amar E, Arteaga-Vazquez J, Bakker MK, Bianca S, Botto LD, et al. Sirenomelia: an epidemiologic study in a large dataset from the International Clearinghouse of Birth Defects Surveillance and Research, and literature review. *Am J Med Genet C Semin Med Genet.* 2011;157(4):358-73.
2. Stocker JT, Heifetz SA. Sirenomelia: a morphological study of 33 cases and review of the literature. *Perspect Pediatr Pathol.* 1987;10:7-50.
3. Kampmeier OF. On sireniform monsters, with a consideration of the causation and predominance of the male sex among them. *Anat Rec.* 1927;34:365.
4. Stevenson RE, Jones KL, Phelan MC, Jones MC, Barr M, Clericuzio C, et al. Vascular steal: the pathogenetic mechanism producing sirenomelia and associated defects of the viscera and soft tissues. *Pediatr.* 1986;78:451-7.
5. Kallen B, Winberg J. Caudal mesoderm pattern of anomalies: from renal agenesis to sirenomelia. *Teratol.* 1974;9:99-111.
6. Rodriguez JI, Palacios J, Razquin S. Sirenomelia and anencephaly. *Am J Med Genet.* 1991;39:25-7.
7. Kohler HG. An unusual case of sirenomelia. *Teratol.* 1972;6:295-301.
8. Jaiyesimi F, Gomathinayagam T, Dixit A, Amer M. Sirenomelia without vitelline artery steal. *Ann Saudi Med.* 1998;18:542-4.
9. Thottungal AD, Charles AK, Dickinson JE, Bower C. Caudal dysgenesis and sirenomelia single centre experience suggest common pathogenic basis. *Am J Med Genet.* 2010;152A:2578-87.
10. Opitz JM, Zanni G, Reynolds JF, GilbertBarnes E. Defects of blastogenesis. *Am J Med Genet.* 2002;115:269-86.
11. Duesterhoeft SM, Ernst LM, Siebert JR, Kapur RP. Five cases of caudal regression with an aberrant abdominal umbilical artery: further support for a caudal regression-sirenomelia spectrum. *Am J Med Genet.* 2007;143A:3175-84.
12. Davidson EH. Later embryogenesis: regulatory circuitry in morphogenetic fields. *Development.* 1993;118:665-90.
13. Gupta S, Araya CE. Potter syndrome. *Medscape Reference,* 2015. Available at: emedicine.medscape.com/article/983477-overview.

Cite this article as: Singh A, Kumari A. Sirenomelia with Potter syndrome: a case report and review of literature. *Int J Reprod Contracept Obstet Gynecol* 2020;9:400-3.